

CASE REPORT

CXR Interpretation: A forgotten Art of Clinical Medicine.

Moazzum Khurshid, Safdar G. khan, Jawed Abubaker
Liaqat National Hospital, Karachi

A 40 year old man presented to emergency room with complain of, fever cough and shortness of breath.

On detail history, he was alright 4 days back when he developed high grade fever which was intermittent associated with cough initially dry; latter productive of purulent sputum was not associated with any shortness of breath. Patient consulted family physician and was given antipyretics along with antitussive and some antibiotics for 2 days.

Patient initially felt better but than developed fever again after a day of stopping his medicine and this time the symptoms were accompanied by felling of shortness of breath especially while exertion and on lying down.

Patient denied any history of smoking or travel during last few months. He has desk job and also denied any history of exposure to any acutely ill person; no history of pets at home.

Physical exam:

A middle aged man with mild respiratory distress with a temperature of 102F and pulse of 120beats /min regular in rate and rhythm.

Chest examination demonstrated a mild decrease breath sound intensity on the right side as compared to the left, without any tenderness and no splinting

A chest radiograph, CBC, Malarial parasite serology, and blood cultures were ordered. Patient was started on broad spectrum

antibiotics with symptomatic treatment, and was admitted to a medical ward.

CBC

Hgb 13.5gm/dl

TLC $18.700 \times 10^9/l$

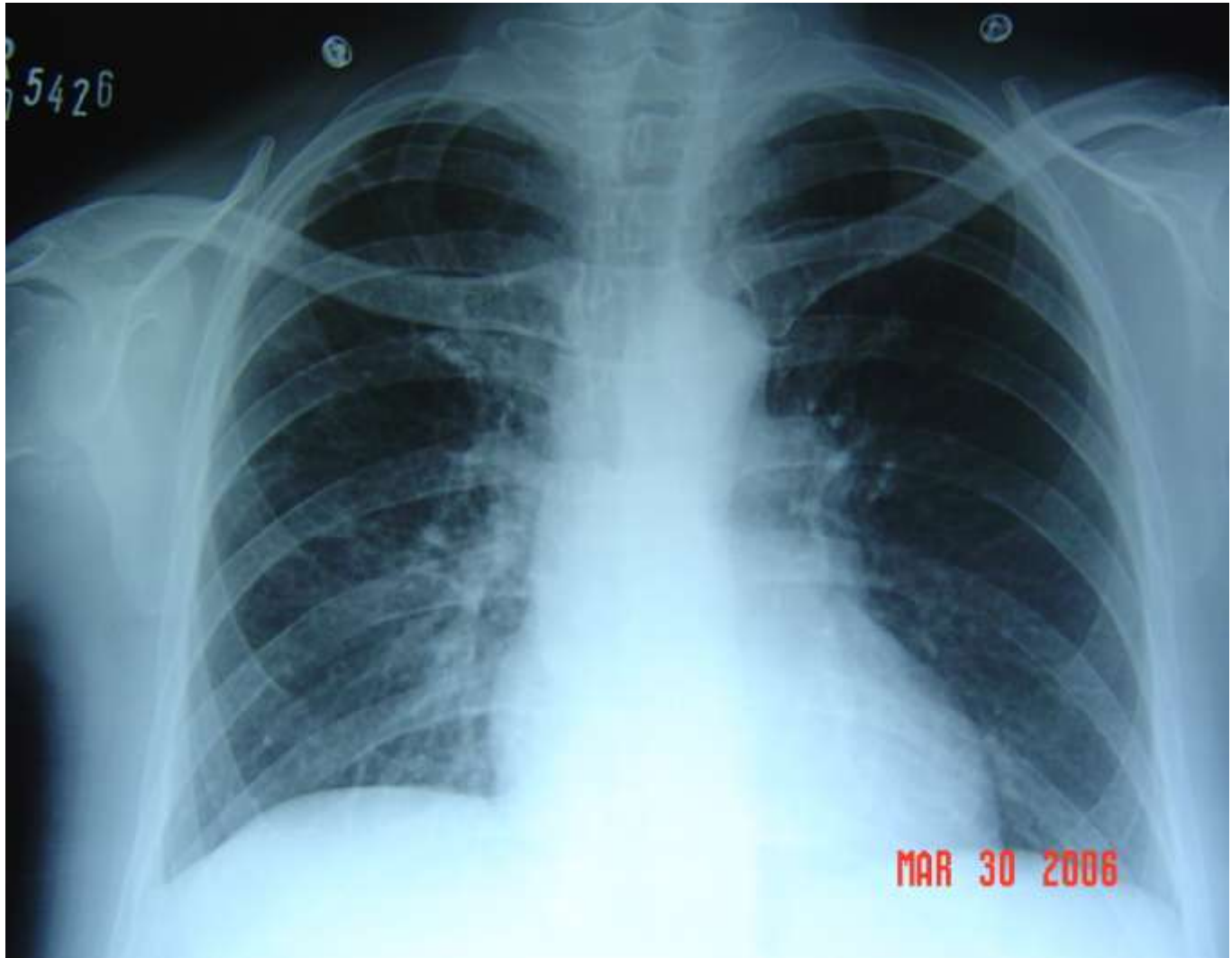
Neutrophils 80%

Lymphocyte 15%

Monocyte 4%

Esinophils 1%

CXR 1



Q) After looking at his CBC and CXR and with this history and physical exam what was missed which may complicate the course of this patient's illness.

A) Subpulmonic (Intrapulmonary) Effusion: Sample of parapneumonic effusion.

Clinician relies a lot on the investigations and timely and proper interpretation of the test can lead to appropriate diagnosis leading to decrease morbidity.

The importance of recognizing pleural effusion on a standard posteroanterior chest roentogram by a junior as well as senior physician cannot be emphasized further, presently with the advent of computer tomography (CT) stress on training of junior physicians interpretation has suffered and it is not unusual that they miss a subtle finding on a routine CXR, which is ordered on almost all medical patient admitted to hospital or assessed in emergency room.

The first description of subpulmonic pleural effusion was made by rigler(1),who consider this location as abnormal; although calling this location abnormal may be a misnomer as in the absence of pleural adhesion fluid normally begins to accumulate in this location and that the large amount may collect before filling of the costophrenic angle. This accumulation of fluid may go undetected until it becomes so large as to cause a pseudodiaphragm caused by the fluid trapped between the base of the lung and the diaphragm in the subpulmonic location leading to discrepancy between the apparent levels of the hemidiaphragms(3).

A condition which displaces diaphragm from its usual position and can simulate subpulmonic effusion, usually are either primarily affecting diaphragm and includes paralysis and eventration of

diaphragm. Liver abscess and subdiaphragmatic abscess, enlarged liver and significant ascites are the few common conditions (4).

A helpful sign to suspect subpulmonic effusion in the presence of relatively small amounts of fluid is; with subpulmonic effusion the pseudodiaphragmatic contour is often peaked more lateral than that of the normal diaphragm(5).

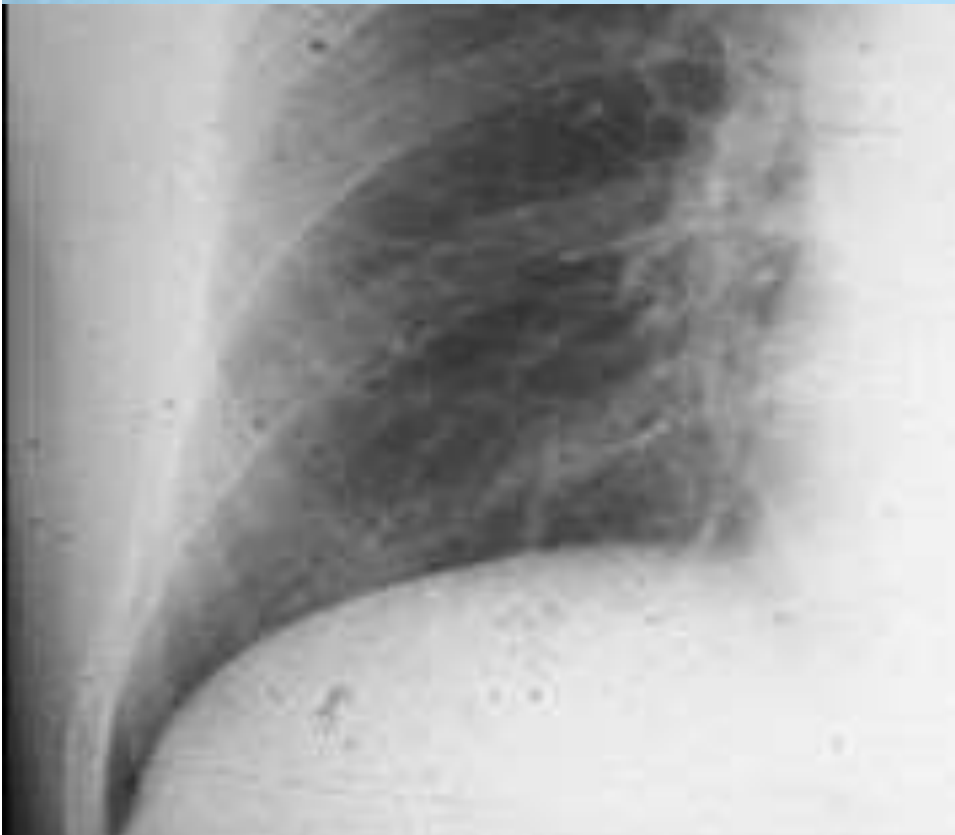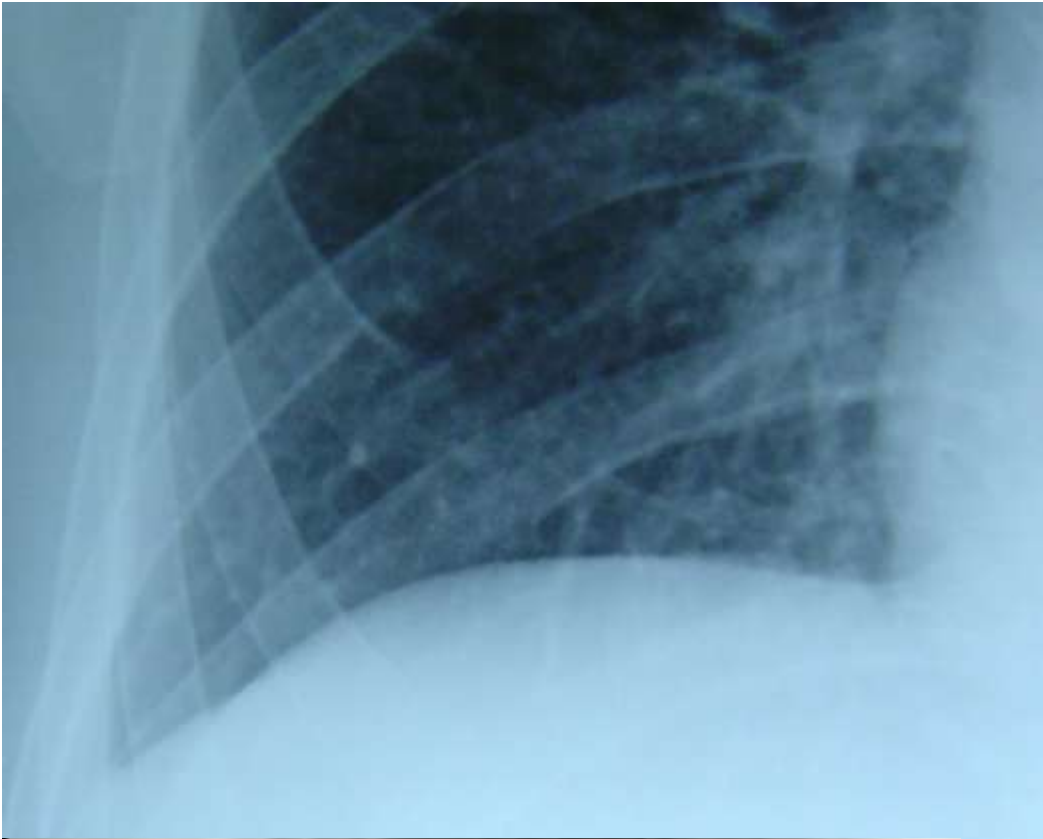
In the presence of fever and high white count with chest X-ray abnormality a suspicion of parapneumonic effusion should be considered and a diagnostic thoracocentesis should be performed after all precautions to differentiate between simple versus complicated parapneumonic effusion as this difference can only be appreciated by pleural fluid analysis (6) and patient course can get complicated if timely tube thoracostomy is not performed.

Hospital course:

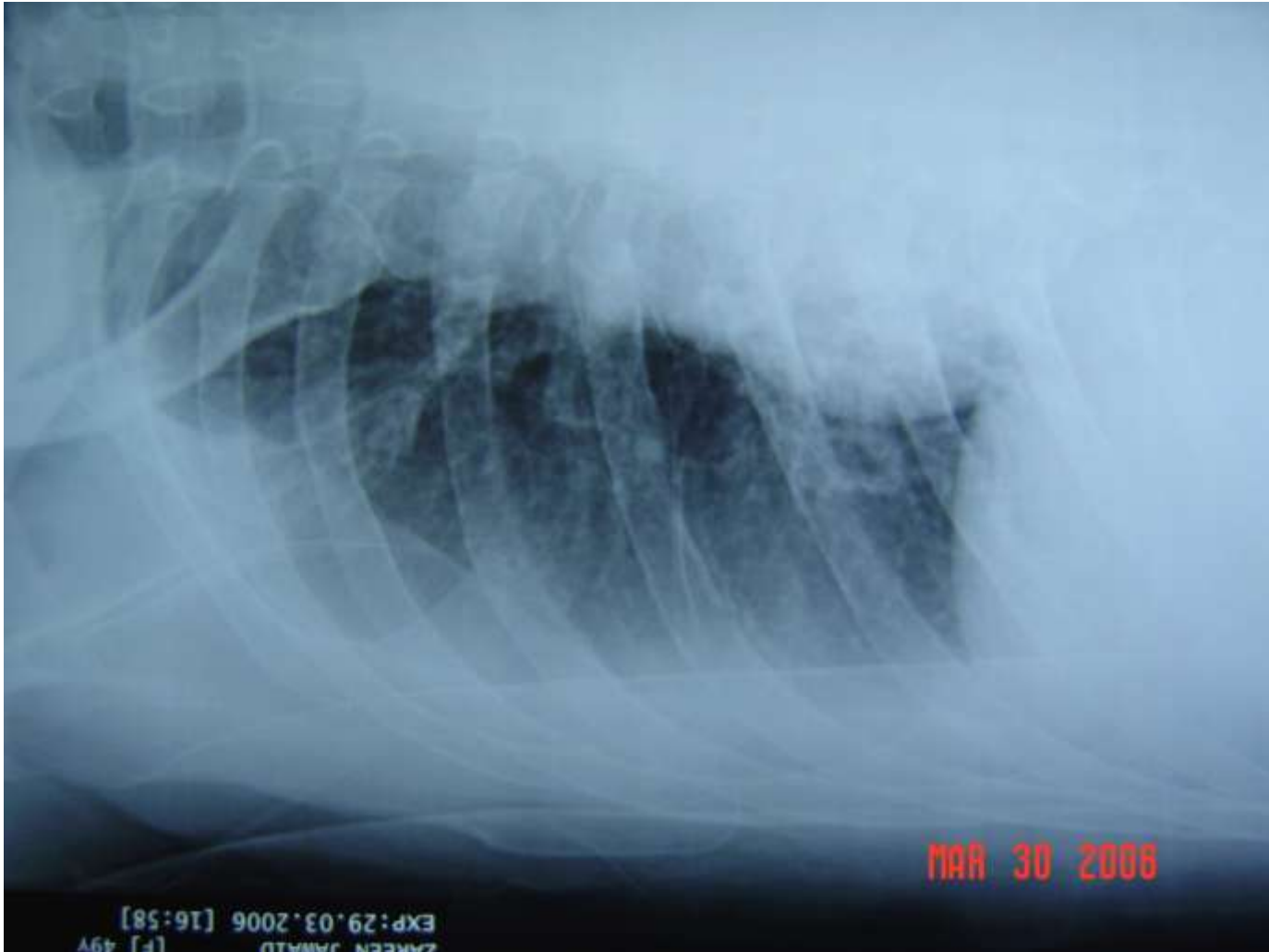
Patient was admitted from ER to a medical ward under an internist, and was treated with antibiotics, cultures were normal and patient continued to have high grade fever with shortness of breath, a pulmonary consult was obtained, and after examination and review of the PA CXR a lateral decubitus film was obtained CXR3, and a diagnostic thoracocentesis was performed which demonstrated a parapneumonic effusion with high LDH 600 IU/dl and moderately low sugar 60mg/dl and border line pH 7.25. Patient underwent Ultra sound guided therapeutic thoracocentesis which demonstrated a completely free flowing effusion without any septa.

After the thoracocentesis patient shortness of breath improved immediately and fever started to subside. Repeat CXR after two days showed no accumulation and after three days patient was switched to oral antibiotics and was discharged home in stable condition.

CXR 2



CXR 4



Clinical Pearls.

- Intrapulmonary accumulation may be unilateral or bilateral. When uni lateral is more common on the right.
- In posteroanterior projection the **peak** of the pseudodiaphragmatic configuration is **lateral** to that of the normal hemidiaphragm, being situated near the junction of the middle and lateral thirds rather than the center, and slopes down sharply towards the lateral costophrenic recess.

- Both the lateral and posterior costophrenic recess may be clear, although in many cases the posterior gutter appears blunted because fluid has spilled over into it.
- On the left side the gas bubble in the fundus of the stomach lies some distance below the dome of the diaphragm.
- A lateral decubitus position with a horizontal X-ray beam should be performed in cases where there is a suspicion for the effusion as it not only confirms the presence of fluid it also allows the estimation of quantity of the fluid.
- In situation where a lateral decubitus film is difficult to obtain, an ultrasonographic examination of the chest may not only allow the confirmation of the fluid and at the same time a ultra sound guided pleurocentesis can be performed for a biochemical and pathological examination.
- Early or minimal pleural effusion may be missed during ultra sound done in supine position.

References:

- 1) Rigler, L. G.: A Roentgenologic observations on the movement of pleural effusions. Amer. J Roentgen. 25: 220, 1931.
- 2) Marvin I. Schwarz, Barry L. Marmorstein: A New Radiological Sign of Subpulmonic Effusion. Chest, 1975, 65: 176-178.
- 3) Rothstein E, Landis F B: Infra pulmonary pleural effusion simulating elevation of the hemidiaphragm. Am J Med 8: 46-52, 1950
- 4) Hessen I: Roentgen examination of pleural fluid. Acta Radiol (suppl) 86: 7-80,1951
- 5) Light, RW, Girad, WM, Jenkinson, SG, et al. AM J Med1980; 69:507.
- 6) Sahn, SA. The sun should never set on a Parapneumonic effusion. Chest 1989; 95: 945.