

# SEVERE KLEBSIELLA PNEUMONIA MIMICKING MIDDLE EAST RESPIRATORY SYNDROME IN A DIABETIC MALE RETURNING FROM SAUDI ARABIA

Talha Mahmud\*, Abdul Hafeez\*, Muhammad Saqib\*, Adnan Najab\*, Muhammad Ramzan\*

\*Shaikh Zayed Hospital & Postgraduate Medical Institute, Lahore - Pakistan

Address for correspondence:  
Prof. Talha Mahmud

Shaikh Zayed Hospital & Postgraduate Medical Institute, Lahore - Pakistan  
E-mail: drmtalha@hotmail.com

## ABSTRACT

A 35 year old diabetic male returned from Riyadh, KSA (April 2014) with history of a recent upper respiratory febrile illness followed by intractable dyspnea and bilateral crackles on chest examination. His chest radiology revealed diffuse bilateral alveolar shadowing and blood gas analysis was consistent with acute respiratory failure in association with deranged liver function tests. Meeting all the clinical criteria, he was managed in strict isolation with precautions as he was a high suspect 'patient under investigation' (WHO/CDC)1 for Middle East Respiratory Syndrome (MERS) versus an acute respiratory viral infection like swine or human influenza or a disseminated bacterial pneumonia. His bronchoalveolar lavage (BAL) specimen along with nasopharyngeal swabs for Middle East Respiratory Syndrome corona virus (MERS Co-V) RT PCR, H1N1 and H5N1 influenza viruses were negative but growth of Klebsiella Pneumoniae on culture was positive. Treatment with appropriate antibiotic lead to complete clinical, biochemical, physiological and radiological recovery.

**KEY WORDS:** Acute respiratory failure, acute respiratory distress syndrome, bronchoalveolar lavage, klebsiella pneumonia, pulmonary edema, Middle East Respiratory Syndrome.

This Article may be cited as: Mahmud T, Hafeez A, Saqib M, Najab A, Ramzan M. Severe klebsiella pneumonia mimicking middle east respiratory syndrome in a diabetic male returning from saudi arabia. Pak J Chest Med 2014; 20(3): 99-103

## INTRODUCTION

**K**lebsiella pneumoniae is a member of the Klebsiella genus of Enterobacteriaceae and humans are the primary reservoir for it; 1 to 6 percent general population carries it in the nasopharynx with higher rates in alcoholics.<sup>2</sup> There is increase prevalence of K. pneumoniae infection in individuals with impaired host defenses including diabetes mellitus, hepatobiliary disease, alcoholism, malignancy, chronic obstructive pulmonary disease (COPD), glucocorticoid therapy, and renal failure.<sup>2,3</sup> K. pneumoniae is a well recognized pathogen in patients with nosocomial pneumonias but is an infrequent cause of community-acquired pneumonia.<sup>2</sup>

Coronaviruses can cause mild to severe illness like common cold as well as severe acute respiratory syndrome (SARS).<sup>1</sup> The new strain of Coronavirus MERS-CoV was first identified in September 2012 among individuals with severe acute respiratory illness in KSA. The infected individuals developed severe acute respiratory illness (acute respiratory failure/ARDS) with symptoms of fever, cough, and shortness of breath. No vaccines and specific antivirals have been developed as yet and

therefore, the supportive treatment remains the mainstay of patient management.<sup>1</sup>

## CASE REPORT

A 35 year old male, resident of Sialkot, employed at Riyadh, KSA for 15 years was suffering from diabetes mellitus (history of moderate glycemic control) and chronic hepatitis B. In middle of April 2014, he went to Makkah for performing 'umrah' accompanying his mother and after seven days of returning to Riyadh, he developed an upper respiratory illness causing throat irritation, sneezing and high grade fever (up to 40°C), cough & small amounts of non purulent sputum. He received medical treatment from a local medical centre but had no relief after five days and started to experience exertional dyspnea (mMRC grade 2). He flew to Pakistan and remained admitted in a private hospital at Sialkot for 2 days but due to worsening in dyspnea (mMRC grade 4), he was referred to Shaikh Zayed Hospital, Lahore where he got hospitalized under pulmonary service. He still had pyrexia, cough with moderately purulent sputum, and worsening dyspnea. There was also history of bleeding gums and nose for 3 days

during this illness. He was an electrician by profession, non smoker and non addict, married with one healthy male child and denied any extramarital relationship. His mother was suffering from hypertension and had recently completed treatment for pulmonary tuberculosis. He was taking metformin and glibenclazide and there was also history of hakeem medication for 2 months prior to this illness.

On examination, he was oriented and alert with a pulse of 112/m, RR 32/m, BP 120/70, temperature of 39 °C and SpO<sub>2</sub> of 90% on room air. His throat was congested and there was bilateral vesicular breathing with prolonged expiration and coarse crackles throughout the chest. He had normally audible first and second heart sounds with tachycardia and mild hepato-splenomegaly while CNS, musculoskeletal and skin examinations revealed no abnormality. His chest radiograph (figure 1) showed normal cardiac size and bilateral perihilar alveolar shadowing extending to peripheral lung zones with relative sparing of apices and bases (resembling pulmonary edema). Arterial blood gas analysis showed pH 7.39, PO<sub>2</sub> 44.1, PCO<sub>2</sub> 33.6, HCO<sub>3</sub> 31.5 mmol, oxygen saturation 87.4% (PO<sub>2</sub>/FIO<sub>2</sub> 210). These findings in the presence of bilateral shadowing on the chest radiograph were consistent with mild ARDS. His laboratory findings included CBC: Hb 14.6, TLC 16.30 (N 84.5%, L 12%, M 3%, E 1%), platelets 106000/cmm, LFTs included total bilirubin 2.1 mg/dL, direct bilirubin 0.9 mg/dL, ALT 182 u/L, AST 426 u/L and alkaline phosphatase 222 u/L, BUN 17 mg/dL and serum creatinine 1.0 mg/dL with normal serum electrolytes and urine routine examination. Hepatitis C and HIV serologies were negative. Urgent HRCT chest showed bilateral diffuse alveolar shadowing with relative sparing of peripheral and apical lung zones (figure 2).

Due to his febrile respiratory illness, bilateral diffuse alveolar infiltrates on chest radiology and respiratory failure with mild ARDS along with deranged liver function tests in a person returning from Riyadh (the epidemic region), there was high clinical suspicion for Middle East Respiratory Syndrome (MERS) versus swine or human influenza or a disseminated bacterial or fungal pneumonia. He was shifted to isolation in a private room with exhaust ventilation at 4th floor and strict contact, eyes and aerosol precautions were under taken while National Institute of Health (NIH, in collaboration with WHO) Islamabad was contacted for further assistance in diagnosis. As advised by NIH experts, his nasopharyngeal swabs were taken and to obtain the lower respiratory specimen, his bronchoscopy was carried out and bronchial washings were taken from both lower lobar segments while BAL was obtained from right middle lobe and specifically sent for MERS Co-Virus RT PCR besides other stains and cultures. He was encouraged oral intake and was given oxygen at 4 L/m via face mask and intravenous azithromycin and Ceftriaxone were started empirically. BAL was positive for growth of Klebsiella Pneumoniae on pyogenic culture with negative Gram, ZN and fungal staining. BAL specimen along with nasopharyngeal swabs for MERS Co-V, H1N1 and H5N1 influenza viruses were also all negative. He was switched to meropenem according to antibiogram while continuing with supportive treatment. Because of high clinical suspicion, the WHO team advised to repeat BAL for MERS Co-V RT PCR that was again negative. On ultrasound examination of abdomen, there was hepato-splenomegaly (liver 17 cm, spleen 16 cm) with mild ascites consistent with chronic liver disease due to hepatitis B. With targeted treatment for klebsiella infection, he was off oxygen and became afebrile within three days and after a total of 10 days treatment, his chest radiograph

**Figure 1: Chest radiograph showing bilateral perihilar alveolar shadowing extending to peripheral lung zones.**

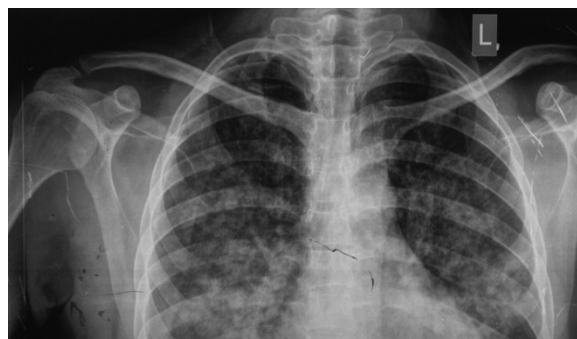

Figure 2: HRCT chest (axial and coronal images) showing bilateral diffuse alveolar shadowing with relative sparing of peripheral and apical zones.

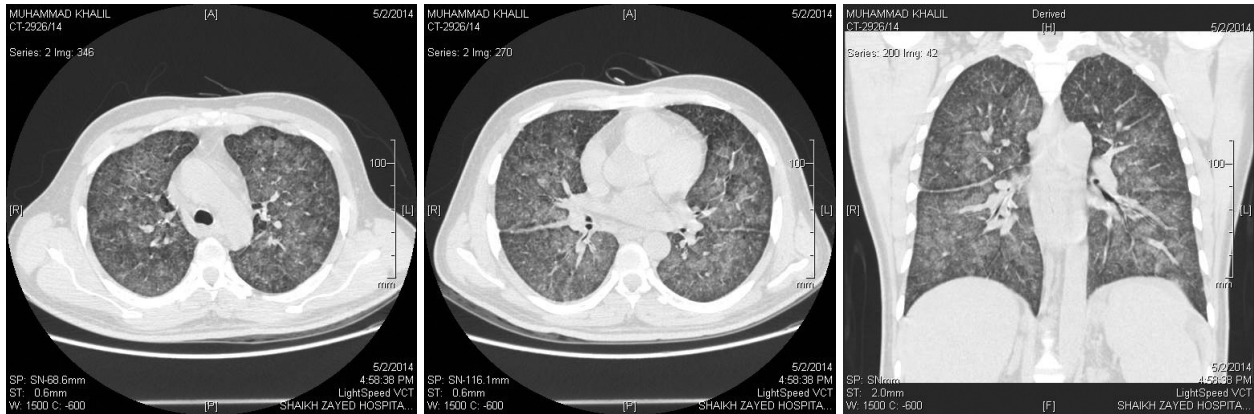
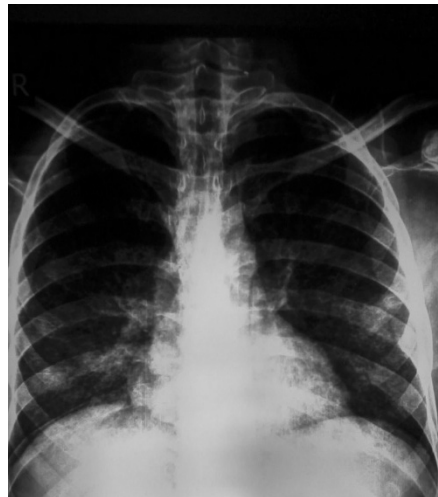

Figure 3: Chest radiograph showing considerable resolution of bilateral pneumonic shadowing.



was clear (figure 3) and serum biochemical abnormalities also returned to normal.

## DISCUSSION

The appearance of any new potentially fatal infectious disease, and uncertainty about its origin and mode of transmission, invariably threatens global health security and also evokes unnecessary and unwarranted fierce scientific competition and discourse, as was illustrated by the HIV AIDS, severe acute respiratory syndrome (SARS), avian and swine influenza epidemics.<sup>4</sup> Many people from Pakistan travel to and from Saudi Arabia and in previous few months there was an international alert for MERS, with CDC and WHO in collaboration with local health agencies published many articles to guide physicians managing these cases.<sup>1</sup> The available evidence suggests that the virus is capable of limited human to human transmission.<sup>1</sup> Besides spread among close family contacts and

healthcare workers, MERS has also been transmitted to other countries through travelers infected in Arabian Peninsula and neighboring countries.<sup>1</sup> A case of MERS is a person with laboratory confirmation (positive PCR) of MERS-CoV infection. Our patient returning from Riyadh with a febrile respiratory illness causing severe respiratory distress and failure was a high suspect for MERS; according to NIH May 2014 guidelines, a person with the following characteristics should be defined as a 'Patient Under Investigation' (PUI) for MERS: A). Fever ( $\geq 38^{\circ}\text{C}$ ,  $100.4^{\circ}\text{F}$ ) and pneumonia or acute respiratory distress syndrome (based on clinical or radiological evidence) AND EITHER: History of travel from countries in or near the Arabian Peninsula within 14 days before symptom onset, OR close contact with a symptomatic traveler who developed fever and acute respiratory illness (not necessarily pneumonia) within 14 days after traveling from countries in or near the Arabian Peninsula OR a member of a cluster of patients with severe acute respiratory illness (e.g. fever and pneumonia requiring hospitalization) of unknown

etiology in which MERS-CoV is being evaluated. OR B). Close contact with a confirmed or probable case of MERS while the case was ill AND Fever (>100°F) or symptoms of respiratory illness within 14 days following the close contact.<sup>1</sup> Due to high clinical suspicion, we followed complete isolation protocol and fortunately our patient's twice BAL was negative for MERS Co-V PCR as well as for swine and human influenza and we could safely discharge him safely to community. To our surprise was the only isolation of klebsiella pneumoniae on BAL culture with excellent response to antibacterial chemotherapy.

K. pneumoniae pulmonary infections include nosocomial (hospital-acquired) pneumonia, community-acquired pneumonia, secondary infection in patients with COPD, lung abscess, and empyema.<sup>2</sup> Klebsiella species account for 3 to 8% of all nosocomial bacterial infections, with the most common manifestations being urinary tract infection, pneumonia, and primary bacteremia.<sup>5</sup> In contrast to its low prevalence as a cause of community acquired pneumonia (CAP) overall, K. pneumoniae constitutes a higher proportion of isolates in more severe infections.<sup>5,6</sup> In different studies, the proportion of K. pneumoniae isolates was 9.5 percent in patients with CAP requiring admission, 11 percent in patients presenting with septic shock, and 22 percent in patients with severe CAP (one-half with shock).<sup>6</sup> Among klebsiella pneumoniae-community acquired infections, diabetes is a particular risk factor for primary liver and lung abscess and community acquired pneumonia.<sup>7</sup> The risk factors of disseminated klebsiella infection in our patient included diabetes, chronic liver disease and probably corticosteroids taken through 'hakeem' medication. Community-acquired K. pneumoniae often produces a lobar pneumonia in contrast to common CT findings in nosocomial K. pneumoniae infection which may include ground glass opacities (100%), alveolar consolidation (91%), intralobar reticular opacities (86 %), and pleural effusions (53%).<sup>3,7</sup> Our patient presented with bilateral diffuse alveolar infiltrates (causing mild ARDS) on chest radiology which was again quite unusual for a community acquired infection caused by klebsiella pneumoniae. Confirmation of diagnosis of K. pneumoniae infection is usually done by culture of blood, sputum, urine, or aspirated body fluid/abscess material, including pleural effusion, pericardial effusion, synovial fluid or cerebrospinal fluid.<sup>8</sup> After the diagnosis of K. pneumoniae infection is well established, the antibiotic regimen is usually determined by the results of drug susceptibility testing.<sup>7,8</sup> Increasing resistance to a broad array of antibiotics is an alarming trend with clinical strains of K. pneumoniae.<sup>7,9</sup> The possibility of production of extended-spectrum beta-lactamases (ESBL) or carbapenemases by klebsiella species that confer resistance to most beta-lactam antibiotics, including penicillins, cephalosporins, and the monobactam aztreonam should be taken into

account when choosing an antibiotic regimen for K. pneumoniae infections as dissemination or outbreaks of ESBL-producing K. pneumoniae strains have been reported worldwide.<sup>9,10</sup>

## REFERENCES

1. Guidelines for the Prevention, Control and Management of Middle East Respiratory Syndrome-Coronavirus (MERS-CoV). WHO Collaborating Centre for Research and Training in Viral Diagnostics. Ministry of National Health Services, Regulations and Coordination. National Institute of Health, Islamabad. Updated May 2014.
2. Podschun R, Ullmann U. Klebsiella spp. as nosocomial pathogens: epidemiology, taxonomy, typing methods, and pathogenicity factors. Clin Microbiol Rev 1998; 11:589.
3. Okada F, Ando Y, Honda K, Nakayama T, Kiyonaga M, Ono A et al. Clinical and pulmonary thin-section CT findings in acute Klebsiella pneumoniae pneumonia. Eur Radiol 2009; 19:809.
4. Zumla AI, Memish ZA. Middle East respiratory syndrome coronavirus: epidemic potential or a storm in a teacup? Eur Respir J. 2014;43:1243-8.
5. Schaberg DR, Culver DH, Gaynes RP. Major trends in the microbial etiology of nosocomial infection. Am J Med 1991; 91:72S.
6. Kollef MH, Shorr A, Tabak YP, Tabak YP, Gupta V, Liu LZ et al. Epidemiology and outcomes of health-care-associated pneumonia: results from a large US database of culture-positive pneumonia. Chest 2005; 128:3854.
7. Wang JL, Chen KY, Fang CT, et al. Changing bacteriology of adult community-acquired lung abscess in Taiwan: Klebsiella pneumoniae versus anaerobes. Clin Infect Dis 2005; 40:915.
8. Garcia San Miguel L, Cobo J, Valverde A, et al. Clinical variables associated with the isolation of Klebsiella pneumoniae expressing different extended-spectrum beta-lactamases. Clin Microbiol Infect 2007; 13:532.
9. Cheng WL, Hsueh PR, Lee CC, Li CW, Li MJ, Chang CM et al. Bacteremic pneumonia caused by extended-spectrum beta-lactamase-producing Escherichia coli and Klebsiella pneumoniae: Appropriateness of empirical treatment matters. J Microbiol Immunol Infect. 2014;1684-1182.
10. Dinubile MJ, Friedland I, Chan CY, et al. Bowel colo-

nization with resistant gram-negative bacilli after antimicrobial therapy of intra-abdominal infections: observations from two randomized comparative clinical

trials of ertapenem therapy. *Eur J Clin Microbiol Infect Dis* 2005; 24:443.