

INCIDENTAL FINDING OF COLOPLEURAL FISTULA DURING PLEURO CUTANEOUS WINDOW SURGERY FOR EMPYEMA THORACIS

Niaz Hussain*, Aneeqa Ahsan Zafar*

*Department of Thoracic Surgery, DOW University of Health Sciences, Karachi, Pakistan.

Address for correspondence:
Aneeqa Ahsan Zafar

Department of Thoracic Surgery, DOW University of Health Sciences, Karachi, Pakistan.

E-mail: aniqaaahsan@hotmail.com

ABSTRACT

We report a 35 year old male patient with a 43 day history of left sided chest pain, shortness of breath and fever. Before presenting to us, he was admitted at a local hospital, where left sided tube thoracostomy was performed for empyema thoracis. After failure of pus to resolve, he was referred to the Department of Thoracic Surgery at Dow University of Health Sciences, Karachi, Pakistan. Pus for gram stain and culture grew multiple organisms and antibiotics were started promptly. The patient's condition did not improve, hence surgery was planned. During surgery, undigested food particles were found in the pleural cavity along with foul smell, suggesting a diagnosis of enteropleural fistula. Barium studies confirmed the diagnosis of colo-pleural fistula. Adopting a staged approach, laprotomy and fistulectomy with primary closure of bowel was attempted. Patient's recovery was unremarkable and he was discharged after eight days.

KEY WORDS: Colopleural fistula, diaphragmatic hernia, empyema

This Article may be cited as: Hussain N, Zafar AA. Incidental finding of colopleural fistula during pleurocutaneous window surgery for empyema thoracis. *Pak J Chest Med* 2014; 20(4): 151-53

INTRODUCTION

Fistulas are abnormal communications between two epithelial-lined surfaces. Gastrointestinal fistulas include all such connections that involve the alimentary tract. Gastrointestinal fistulas can be external if they communicate with the skin surface i.e. enterocutaneous fistula & internal if they connect to another internal organ, system or space. Colopleural fistula is a rare entity. Possible cause include hepato gastrointestinal surgery, fistula secondary to diaphragmatic hernia¹ malignancy, complication of pneumonectomy² and diverticular disease.³

CASE REPORT

We report a case of 35 year old male patient referred from a local hospital in Sindh. He was received in a cachexic, septic condition with a left sided chest tube in place discharging foul smelling pus. According to the patient, around 2 months back, he developed abdominal pain with constipation and vomiting. He received conservative management at a local hospital and was discharged after a week. About 12 days later, he started spiking a fever and developed left sided chest pain. He was diagnosed with left hydropneumothorax with possible empyema formation and a tube thoracostomy was performed. Chest tube bottle collected more than a litre of frank pus, so antibiotics were started and the

patient was referred to our department.

We sent Culture and sensitivity of pus which reported growth of Ecoli, Proteus mirabilis and Streptococci. Despite appropriate antibiotics, the patient's condition continued to deteriorate rapidly. As his condition did not permit any major surgical interventions, we decided to create a pleurocutaneous window to drain the foul smelling pus. During the procedure, the lung was found to be collapsed and there were no pleural adhesions. We were surprised to find undigested food particles in the pleural cavity at the diaphragmatic site and a small opening was seen at the diaphragm.

Suspecting a possible enteropleural fistula, patient was kept NPO and total parenteral nutrition started. It was observed that while patient was NPO his pus discharge decreased significantly which was suggestive of Sister Leena's Sign.² The fistulous communication was confirmed on barium enema which showed contrast entering the pleural cavity. After confirmation of fistulous communication, elective laparotomy was planned. During surgery, the splenic flexure of colon was found entrapped within the left dome of diaphragm with underlying diaphragmatic hernia. The colon appeared healthy on assessment, so the fistula tract was excised and the intestine was repaired in two layers. The defect in diaphragm was also closed. Colonic tissue specimen was sent for histopathology which revealed

a nonspecific inflammatory infiltrate without any obvious pathology. Patient's post-op recovery was smooth and he was orally allowed on the 6th postoperative day.

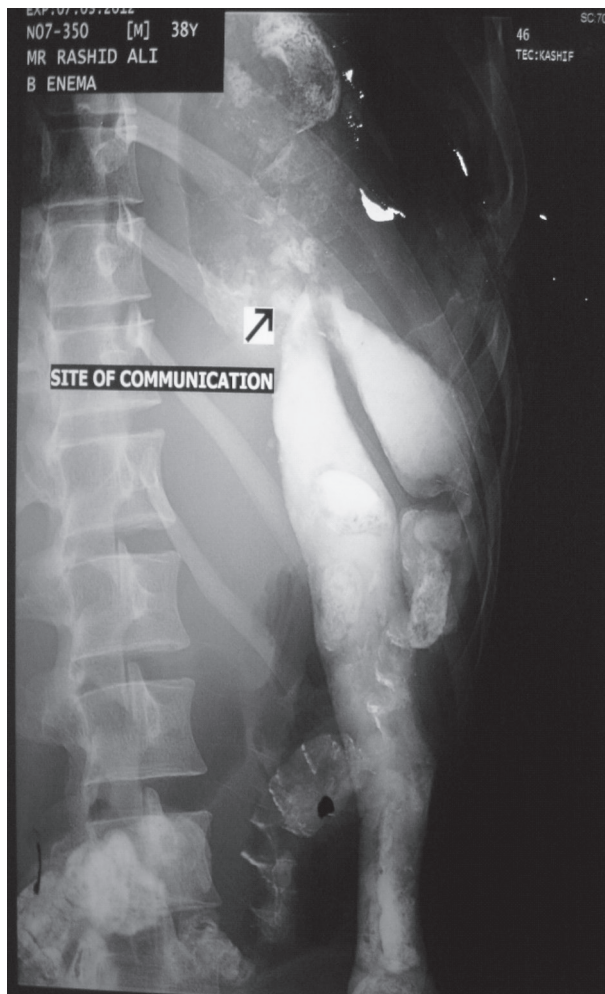


Figure 1: Barium enema showing splenic flexure communicating with left thoracic cavity

DISCUSSION

Feculent empyema thoracis is a very uncommon presentation of diaphragmatic hernia. Our literature review revealed similar cases in which colopleural fistula was diagnosed as an incidental finding secondary to diaphragmatic hernia repair,¹ due to sigmoid perforation⁴ or resulting as a complication post pneumonectomy.^{2,5} While traumatic diaphragmatic hernia is a well-recognized complication of blunt and penetrating injuries to the abdomen and thorax,⁶ strangulation of the large bowel that migrates through that hernia into the thorax with subsequent rupture and the development of fecal pneumothorax is most unusual.⁶ The clinical presentation of traumatic diaphragmatic hernia maybe acute or delayed in its appearance. Late presentations may be dramatic if they occur months or years after the initial



Figure 2: Fistulectomy being performed

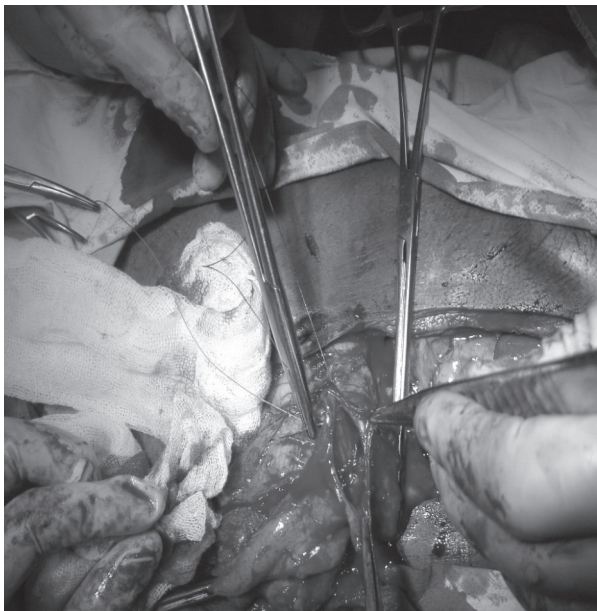


Figure 3: Large bowel repair being done

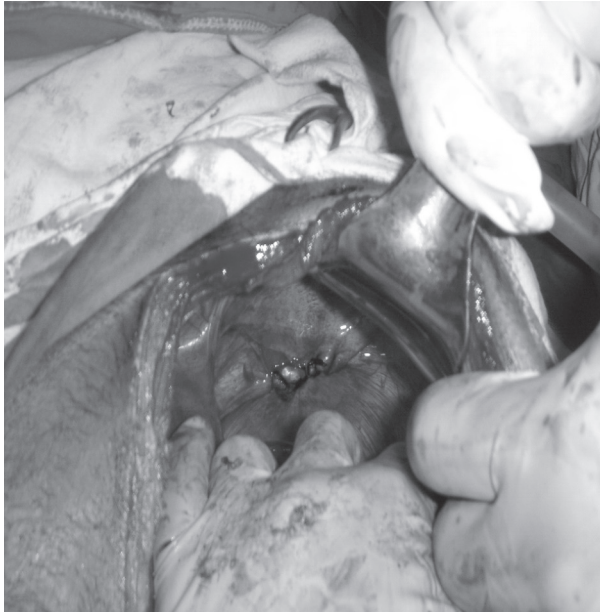


Figure 4: Diaphragmatic repair

injury.^{4,6} During history taking, our patient recalled two injuries from adolescence, one inflicted with a knife on the left side of his chest, managed by primary closure and another injury that resulted after a fall from the back seat of a loader vehicle but he did not receive any treatment for it.

Patients with colopleural fistula usually present like empyema thoracis, with fever, chest discomfort and dyspnea.¹ Diagnosis requires a high degree of suspicion. Presence of a foul smelling thickened discharge should raise the possibility of fistula formation.³ Observing sister leena's sign may aid in diagnosis.² In our case, the detection of coliforms in culture, polymicrobial flora on gram stain⁶ and presence of fecal pyopneumothorax along with the correlation of amount of pus with food intake was highly suggestive of colopleural fistula. Definite diagnosis requires barium imaging. Recommended method of treatment of this pathology is a laparotomy or thoracotomy either as urgent surgery once diagnosed³ or a staged procedure after stabilization of the patient with TPN and antibiotics and definitive surgery.

CONCLUSION

Diagnosis of colopleural fistula is a challenge. It is important to diagnose it early to avoid patient morbidity. Presence of foul smelling discharge with pyopneumothorax, growth of polymicrobial flora on gram stain with E coli detection and a decrease in discharge following reduction in food intake should raise the suspicion of a colopleural fistula.

REFERENCES

1. Komatsu T, Henteleff H. Colopleural fistula with atypical presentation as a complication of diaphragmatic hernia repair. *Ann Thorac Surg* 2010;90:662-3.
2. Ibrahim WH, Thomas L. Sister Leena's sign: a sign that may be useful in differentiating colopleural fistula (fecal empyema) from usual empyema. *Chest* 2007;131:1616-7.
3. Barisiae G, Krivokapiae Z, Adziae T, Pavloviae A, Popoviae M, Gojniae M. Fecopneumothorax and colopleural fistula - uncommon complications of Crohn's disease. *BMC Gastroenterol* 2006;6:17.
4. Papagiannopoulos K, Gialvalis D, Dodo I, Darby MJ. Empyema resulting from a true colopleural fistula complicating a perforated sigmoid diverticulum. *Ann Thorac Surg* 2004;77:324-6.
5. Olubaniyi BO, Fontaine EJ, Page RD. Colo-pleural fistula following pneumonectomy. *Eur J Cardiothorac Surg* 2006;30:950-1.
6. Lacayo L, Taveras JM, Sosa N, Ratzan KR. Tension fecal pneumothorax in a postpartum patient. *Chest* 1993;103:950-1.