

## CASE REPORT

# ALL THAT GLITTERS IS NOT GOLD. CONSOLIDATION, PYREXIA AND LEUCOCYTOSIS. CRYPTOGENIC ORGANIZING PNEUMONIA MIMICKING COMMUNITY ACQUIRED PNEUMONIA.

*Talha Mahmud, Muhammad Saqib and Guness Mal*

### ABSTRACT:

An elderly male office worker in a ceramics factory, known to have coronary heart disease and hepatitis C related chronic liver disease was hospitalized with fever, leucocytosis and bilateral peripheral patchy alveolar infiltrates. He was prescribed empirical antibiotics and underwent various investigations including high resolution CT chest after which broncho-alveolar lavage and transbronchial biopsies were performed that were consistent with mixed cellularity and bronchiolitis obliterans organizing pneumonia (BOOP) on histology, respectively. He was treated with prednisolone in tapering doses that lead to clinical and radiological resolution.

**Key words:** Bronchiolitis obliterans organizing pneumonia, bronchoalveolar lavage, cryptogenic organising pneumonia, peripheral alveolar infiltrates, transbronchial biopsy.

---

### INTRODUCTION:

Organizing pneumonia is a condition which can be seen in association with connective tissue diseases, exposure to a variety of drugs, malignancy, and other interstitial pneumonias.<sup>1</sup> The idiopathic form of organizing pneumonia is called cryptogenic organizing pneumonia (COP) which was formerly called idiopathic bronchiolitis obliterans organizing pneumonia or BOOP.<sup>2</sup> Clinically this condition usually presents with features resembling a pneumonic illness and BOOP should be considered whenever community-acquired pneumonia fails to respond to therapy.<sup>1</sup> Spontaneous improvement is rare and the condition is treated with corticosteroids and sometimes with other immunosuppressive agents.<sup>3</sup>

### CASE REPORT:

A 70 year old never smoker male was hospitalized with a history of progressive exertional dyspnea, cough with mild yellowish sputum and persistent fever of 100-101 °F having 6 weeks duration. There was no history of nocturnal awakening due to shortness of breath, wheezing, no hemoptysis or chest pain. His review of systems showed stable weight and no evidence of rhinitis or sinusitis including no other systemic complaints. He was given broad spectrum antibiotics (cefepime and moxifloxacin for 10 days) by his family physician but there was no relief in his symptoms. He was suffering from coronary heart disease, hypertension and diabetes mellitus; all were controlled with medical treatment. In the past, he was never hospitalized for any medical or surgical ailment.

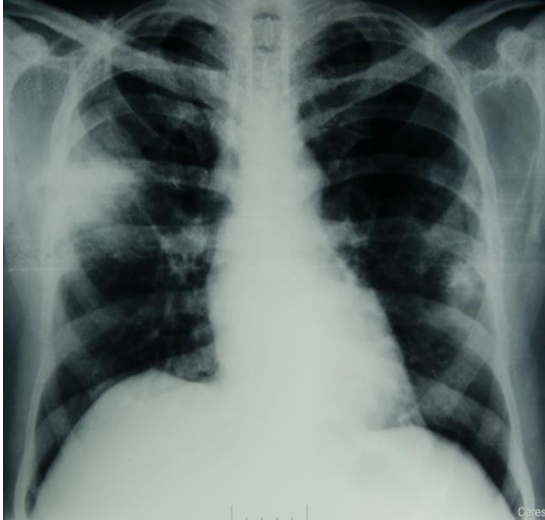
---

*Department of Pulmonology, Shaikh Zayed Hospital, Lahore, Pakistan.*

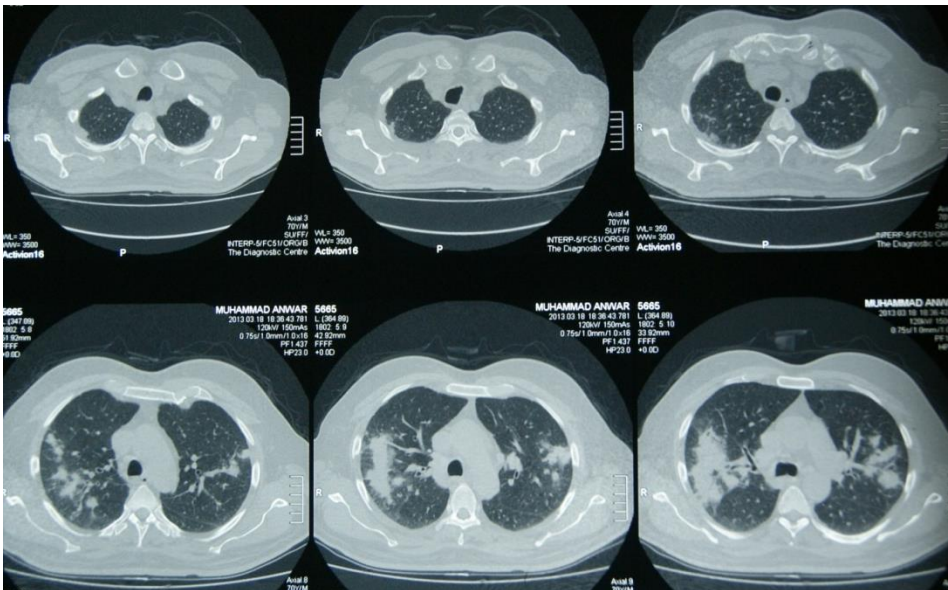
He kept no pets or birds at home, denied any aerosol or chemical exposure and revealed his job to be confined to office in the premises of his own ceramics factory. He was married with three healthy children and his family history was positive for diabetes mellitus. He was using lantus insulin, losartan potassium, isosorbide mononitrate and acetyl salicylic acid for his afore mentioned medical problems.

On general physical examination, he was alert & cooperative, febrile with a temperature of 101<sup>0</sup>F regular pulse 90/m, blood pressure 125/78 mmHg & respirations were 22/m with 95% saturation (post exertion 92%) on pulse oximeter. Chest examination was consistent with bilateral coarse crackles and increased vocal resonance in middle to lower parts of chest bilaterally both anteriorly and posteriorly. Remaining general and systemic examination was normal. Laboratory evaluation showed a hemoglobin of 13 g/dL, WBC count 13000/cmm and platelets 250000/cmm. His serum biochemical analysis included blood urea nitrogen 51 mg/dL, creatinine 1.6 mg/dL, albumin 2.5 mg/dL while other liver function tests and electrolytes were within the normal range. Chest radiographic findings included preserved lung volumes with bilateral peripheral patchy areas of opacification involving right middle and left middle and lower zones (figure I). His spirometry was carried out that showed moderate restriction and arterial blood gas analysis revealed pH 7.39, PO<sub>2</sub> 85 mmHg, PCO<sub>2</sub> 34 mmHg and HCO<sub>3</sub> 22 mmol/L. High resolution computerised tomography of the chest was consistent with patchy opacities predominantly involving peripheral lung zones, with relative sparing of apices and lower lobes (figure II and III). Sputum analysis for Gram staining, ZN staining, fungal smear and pyogenic bacterial culture was negative. ECG showed chronic left bundle branch block pattern and echocardiography revealed segmental wall motion defects involving left side of heart (ejection fraction 35 %).

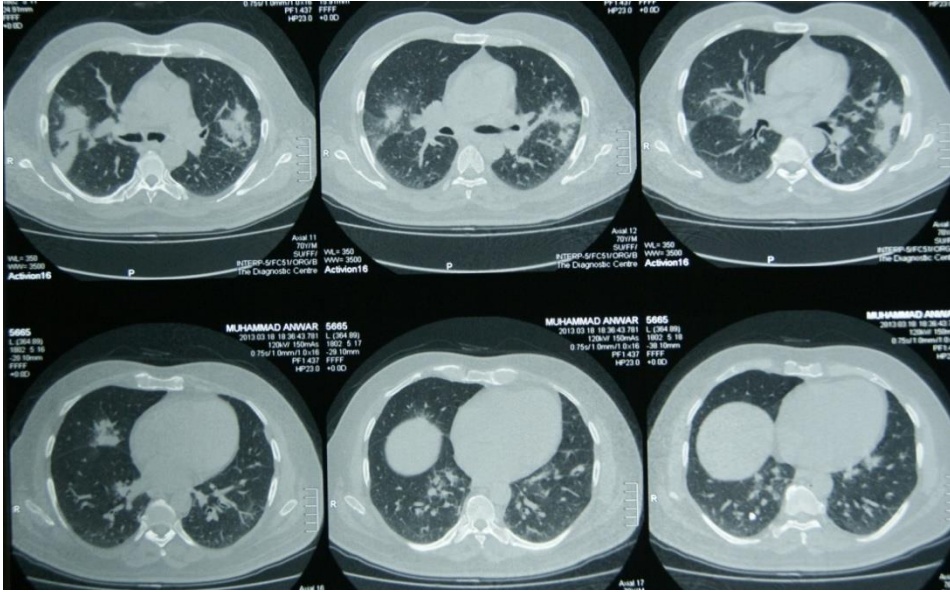
He underwent bronchoscopy that showed normal mucosal color, texture, sub-carinae and orifices up to sub-segmental level on both sides of bronchial tree. Bronchoalveolar lavage was taken from anterior segment of right upper lobe and 7 bites of transbronchial biopsy were taken from the same segment under fluoroscopic guidance (figure 4). Pathological evaluation revealed lung parenchyma showing peri-bronchial plugs of loose matrix, rich connective tissue & chronic inflammatory cells with adjacent alveoli showing collection of foamy histiocytes & type 2 pneumocytes hyperplasia, consistent with bronchiolitis obliterans with organizing pneumonia. In the light of this clinical presentation, radiological features of peripheral patchy consolidations and histopathology, he was finally diagnosed as having cryptogenic organising pneumonia (COP). He was given 13 valent pneumococcal vaccine (advised for 23 valent shot after 8 weeks) and started with oral prednisolone 40 mg/day for 6 weeks and then tapered to 20 mg/day over next 8 weeks and was advised to continue it for a total of 6 months. His follow up chest radiograph after 6 weeks (figure 5) showed considerable resolution of shadowing bilaterally along with resolution of fever and respiratory symptoms.



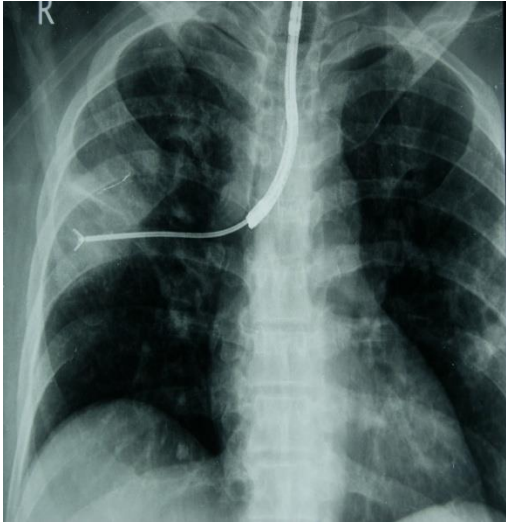
**Figure I:** CXR-PA: Patchy peripheral opacities; larger in right middle zone and smaller in left middle and lower zones.



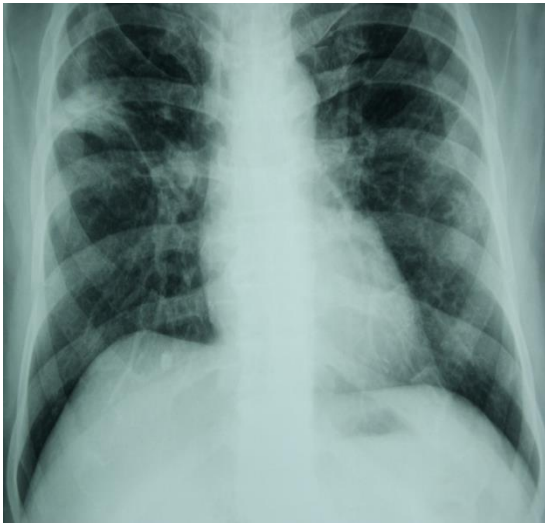**Figure II:** HRCT Chest: Patchy opacities predominantly involving peripheral lung zones at and below the level of aortic arch, with sparing of apical regions.



**Figure III:** HRCT Chest: Patchy opacities predominantly involving peripheral lung zones at and below the level of heart, with relative sparing of lower lobes.



**Figure IV:** CXR-PA: Transbronchial lung biopsy through bronchoscope under fluoroscopic guidance from peripheral opacity in right middle zone.



**Figure V:** CXR-PA: Follow up at 6 weeks after treatment with corticosteroids showing bilateral considerable improvement in opacities.

## **DISCUSSION:**

COP is a distinct clinical entity with predominant features of pneumonia, rather than a primary airway disorder.<sup>2</sup> Pathologically, COP is characterized by excessive proliferation of granulation tissue within small airways (proliferative bronchiolitis) and alveolar ducts, associated with chronic inflammation in the surrounding alveoli, filled with foamy macrophages.<sup>4</sup> The disease onset is typically in the fifth or sixth decades of life, with men and women affected equally.<sup>5</sup> The clinical presentation of COP often mimics that of community-acquired pneumonia and in one-half of cases, the onset is heralded by a flu-like illness with fever, malaise, fatigue, and cough.<sup>6</sup> Laboratory findings include leucocytosis (50 percent), elevated initial ESR and a positive C-reactive protein (70 to 80 percent) while auto-antibodies are usually negative or present in very low titer.<sup>6, 7</sup> Pulmonary function tests predominantly demonstrate a restrictive pattern, and airflow obstruction is uncommon in patients who are not smokers with reduction in diffusing capacity in 72% of patients.<sup>8</sup>

The radiological findings on plain chest radiograph may include bilateral, diffuse ground-glass or consolidative opacities in the presence of normal lung volumes, peripheral opacities, and rarely irregular linear or nodular opacities, pleural effusion, pleural thickening, hyperinflation, and cavities; computed tomographic (CT) lung scans often reveal patchy air-space consolidation more frequently in the periphery of the lower lung, ground-glass opacities, small nodular opacities, and bronchial wall thickening with dilation.<sup>9</sup>

Diagnosis can be established by finding characteristic pathological lesions and broncho-alveolar lavage (BAL) findings in a typical clinical and radiological scenario suggestive of BOOP. BAL typically shows mixed pattern of increased cellularity (lymphocytes, neutrophils, and eosinophils) and open or thoracoscopic lung biopsy is suggested to confirm the diagnosis if transbronchial lung biopsies do not provide ample lung tissue.<sup>4</sup> The prognosis is good with glucocorticoid therapy which induces rapid clinical & radiological improvement, usually without significant sequelae while relapses are common upon stopping or reduction of glucocorticoids, often leading to prolonged treatment with corticosteroids, or other immunosuppressive agents.

## **REFERENCES:**

1. Ryu JH, Myers JL, Swensen SJ. Bronchiolar disorders. *Am J Respir Crit Care Med* 2003; 168:1277-92.
2. Cordier JF. Cryptogenic organising pneumonia. *Eur Respir J* 2006; 28:422-46.
3. Izumi T, Kitaichi M, Nishimura K, Nagai S. Bronchiolitis obliterans organizing pneumonia. Clinical features and differential diagnosis. *Chest* 1992; 102:715-9.
4. Cottin V, Cordier JF. Cryptogenic organizing pneumonia. *Semin Respir Crit Care Med*. 2012:462-75.
5. Muller NL, Guerry-Force ML, Staples CA, Wright JL, Wiggs B, Coppin C et al. Differential diagnosis of bronchiolitis obliterans with organizing pneumonia and usual interstitial pneumonia: clinical, functional, and radiologic findings. *Radiology* 1987; 162:151-56.

6. American Thoracic Society/European Respiratory Society International Multidisciplinary. *Am J Respir Crit Care Med.* 2002;165:277-304.
7. Kang BH, Park JK, Roh JH, Song JW, Lee CK, Kim M et al. Clinical significance of serum autoantibodies in idiopathic interstitial pneumonia. *J Korean Med Sci.* 2013;731-7.
8. Horton DK, Berkowitz Z, Kaye WE: The public health consequences from acute chlorine releases, 1993–2000. *J Occup Environ Health* 2002; 44:906-913.
9. Franquet T, Giménez A. Idiopathic interstitial pneumonias. *Radiologia.* 2012;54(6); 479-89.
10. Oymak FS, Demirbaş HM, Mavili E, et al. Bronchiolitis obliterans organizing pneumonia. Clinical and roentgenological features in 26 cases. *Respiration* 2005; 72:254-62.